

## LETTER - RESEARCH

### A retrospective study of oral tofacitinib therapy for alopecia areata<sup>☆</sup>



Dear Editor,

Alopecia Areata (AA) is an autoimmune non-scarring alopecia with an overall prevalence of around 2%.<sup>1</sup> Treatment of moderate to severe AA is challenging. Retrospective studies have demonstrated that tofacitinib may induce hair regrowth in patients with moderate to severe AA.<sup>2-7</sup> While the safety and efficacy of tofacitinib in severe AA were supported in these studies, the durability of treatment has not been extensively documented.

In this retrospective cohort study, approved by Mass General Brigham Institutional Review Board, the authors have systematically explored the long-term efficacy, safety, and durability of tofacitinib for the treatment of AA. The authors were also interested in evaluating the impact of the temporary discontinuation of tofacitinib on the course of AA during the COVID pandemic.

Using a centralized clinical data registry from various hospital systems, the authors identified patients with AA that had received tofacitinib until February of 2021. Eligible patients had a diagnosis of AA and received systemic tofacitinib for a minimum of three months (Fig. 1).

Diagnosis of AA was confirmed by a review of the patient's medical record. All patients had AA for at least six months and were followed by a dermatologist. Information on the severity or proportion of scalp involvement, when available, was collected from dermatologist notes. Most of the patients excluded never started tofacitinib (lack coverage or safety concerns). Others had not been seen after tofacitinib had been prescribed, were taking tofacitinib for another indication, and did not have concomitant AA.

Treatment response was categorized as complete (almost or total regrowth) and non-complete (partial or minimum), based on the providers' notes. The authors evaluated demographics and disease characteristics between complete and non-complete using Mann-Whitney and Fisher Exact (SPSS 20.2, IBM, Armonk, NY).

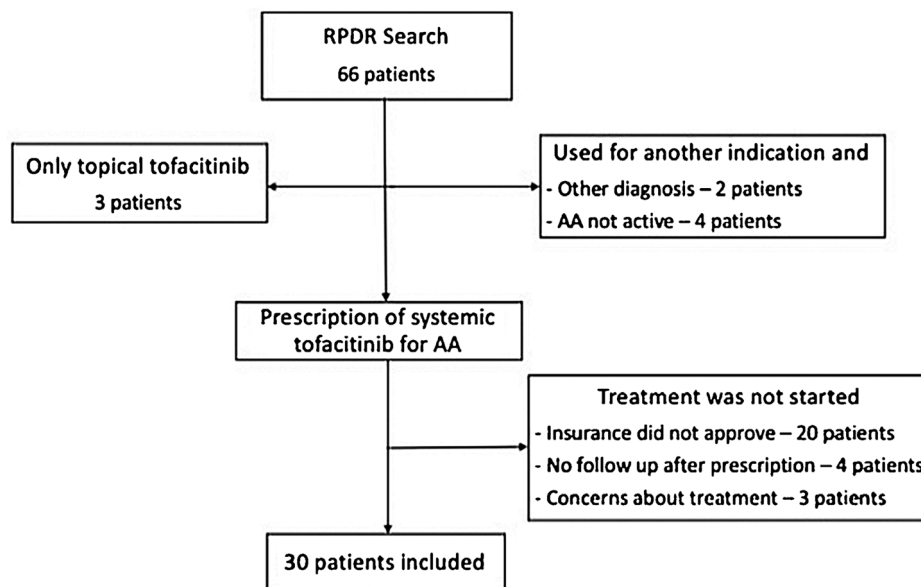


Figure 1 Patient selection flowchart.

<sup>☆</sup> Study conducted using registries from Massachusetts General Brigham hospital systems, Boston, Massachusetts, United States.

**Table 1** Patient and disease characteristics that may affect complete response.

	All patients (n = 30)	Complete Responders (n = 20)	Non-complete responders (n = 10)	p-value
<b>Age<sup>a</sup>, yr</b>	34 (12–63)	31 (14–64)	54 (17–64)	0.25
<b>Female</b>	23 (76.7)	16 (80.0)	7 (70.0)	0.66
<b>Race/Ethnicity</b>				
Caucasian, non-Hispanic	22 (73.3)	16 (80.0)	6 (60.0)	0.02
African American, non-Hispanic	4 (13.3)	0	4 (40.0)	
Asian, non-Hispanic	1 (3.3)	1 (5.0)	0	
Hispanic	3 (10.0)	3 (15.0)	0	
<b>BMI, kg/m<sup>2a</sup></b>	23.5 (17.6–41.1)	23.0 (17.8–40.6)	23.9 (17.6–41.1)	0.96
<b>Scalp involvement (%)</b>	100 (10–100)	90 (10–100)	100 (all)	0.03
<b>Disease duration<sup>a</sup>, yr</b>	5.0 (0.5–45)	4.5 (0–28)	8.5 (2–45)	0.14
<b>Current episode duration<sup>a</sup>, yr</b>	1.0 (0.5–21)	1 (0–7)	3.5 (1–21)	<0.001
<b>Other autoimmune disease</b>	15 (50.0)	13 (65.0)	2 (20.0)	0.05
Thyroid disease	6 (20.0)			
Inflammatory Bowel Disease	3 (10.0)			
Arthritis	2 (6.7)			
Vitiligo	2 (6.7)			
Psoriasis	1 (3.3)			
Atopic dermatitis	1 (3.3)			
<b>Neutrophilic dermatosis</b>	1 (3.3)			
<b>Nail changes (n = 24)</b>	6 (20.0)	2 (11.1)	4 (66.7)	0.02
<b>Previous systemic therapies</b>				
Systemic steroids	20 (66.7)	13 (65.0)	7 (70.0)	1.00
Methotrexate	6 (20.0)	4 (20.0)	2 (20.0)	1.00
Cyclosporine	2 (6.7)	2 (10.0)	0	0.54
<b>Treatment duration, months</b>	18.6 (3.1–68.9)	28.3 (6.1–68.9)	6.2 (3.1–29.6)	<0.001

<sup>a</sup> When patients started tofacitinib therapy. Continuous variables are presented as median (range) and categorical as number (%).

The present study included 30 AA patients. Sixty percent had totalis or universalis and 20%, ophiasis (Table 1). AA in four patients was potentially triggered by an anti-TNF agent, used to treat an additional inflammatory disease. All patients had previously received topical or intralesional steroids and 21 had taken other systemic therapies.

In the present sample, a long duration of the current AA episode, an increased proportion of scalp involvement, and the presence of nail changes and other autoimmune diseases were significantly associated with a poor response. While all Hispanic patients were complete responders, all African American patients were non-complete responders. All 4 patients considered to have anti-TNF- $\alpha$ -triggered AA had a complete response to tofacitinib upon discontinuation of the anti-TNF- $\alpha$  agent.

Twenty patients achieved a complete response to tofacitinib (Table 2). Four had a few episodes of mild to moderate exacerbation that responded either to intralesional steroid injections or an increased dose of tofacitinib (10 mg BID). Ten patients had either no, minimal, or partial response to tofacitinib.

Most patients received long-term therapy. Nineteen patients completed a year of therapy and 10 patients had been treated for more than 2.5 years. Initial signs of regrowth were noted in 12 (4–61) weeks.

Seven patients discontinued tofacitinib for 2–4 weeks. None experienced significant worsening and continued to respond when tofacitinib was restarted. Two other patients, initial responders, after discontinuing tofaci-

**Table 2** Response to systemic tofacitinib.

Treatment duration, months	18.6 (3.1–68.9)
Treatment lasting more than 12 months	19 (63.3)
Treatment lasting more than 30 months	10 (33.3)
<b>Response to treatment</b>	
Complete/almost complete	20 (66.7)
Partial	6 (20.0)
Minimal/no response	4 (13.3)
First time response was noted, weeks	12.0 (4.3–61.0)
Full regrowth achieved, weeks	32.9 (19.6–176.1)
Response duration, weeks	77.9 (5.3–273.3)
<b>Need for additional therapy</b>	
Intralesional steroid injection	7 (23.3)
Prednisone taper	2 (6.7)
Increase tofacitinib dosage (10 mg BID) <sup>a</sup>	16 (53.3)
Oral minoxidil (2.5 mg QD)	1 (3.3)

<sup>a</sup> Initial dose was 5 mg BID, increased to a maximum of 10 mg BID, if regrowth was not achieved at follow up. Continuous variables are presented as median (range) and categorical as number (%).

tinib due to lack of insurance, promptly lost all regrown hair.

Table 3 displays the safety information for this cohort. Two patients had a severe infection requiring hospital admission, including one patient hospitalized for a UTI who had

**Table 3** Safety – Adverse events noted during dermatology consultations.

AE	Number of patients	Comments
Severe infection	2	Both admitted to the hospital because of complicated UTI and COVID-19 pneumonia, respectively
COVID	3 <sup>a</sup>	Only 1 was admitted to the hospital and was later discharged.
HPV infection	3	
Herpes Zoster	1	
Tuberculosis	0	
Increased Lipids	11 <sup>b</sup>	1 Discontinued therapy <sup>c</sup>
Increased LFTs	2	1 Discontinued therapy <sup>c</sup>
Acneiform Eruption	3	Mild
Maculopapular Eruption	1	Discontinued
DVT – Thrombosis	0	
New Malignancy	1	1 BCC

<sup>a</sup> Out of 9 patients tested for COVID-19.

<sup>b</sup> Including 2 patients with pre-existing hyperlipidemia that became worse after receiving tofacitinib.

<sup>c</sup> Same patient, therapy had not been effective after 8 months. After an increase in LFTs and lipids, tofacitinib was discontinued.

Crohn's disease with a fistula and one obese patient with severe COVID. Two patients discontinued because of adverse events: an acute skin rash and progressively increased liver enzymes and lipids. Aside from a basal cell carcinoma diagnosed during the fifth year of tofacitinib, there were no other malignancies reported. There were no reports of thrombosis or tuberculosis. Four patients discontinued tofacitinib because of absent or minimal response.

This retrospective study demonstrated that tofacitinib is an effective treatment option for AA. Long-term continuous therapy produces a stable and durable response. Even for patients that temporarily held therapy, the response was either maintained or restored.

A retrospective analysis of 90 patients demonstrated that, among 65 patients with a current episode duration of 10 years or less, 20% were complete responders (> 90% change in SALT score).<sup>6</sup> In other studies, a response greater than 50% change in SALT score has been demonstrated in 32%–56% of patients<sup>2,3,7,8</sup> and a 90% change in 28% of patients.<sup>7</sup> The proportion of complete responders in the present study was much higher (67%), possibly related to much longer follow-up time. Some of the patients achieved complete regrowth only after 2 years of therapy.

Among potential factors that may affect treatment response, an increased proportion of scalp involvement, longer duration of current episode, presence of nail changes, or other autoimmune diseases were significantly associated with non-complete response in the present sample. There was also a significant association between race and response, with all African American patients being among non-complete responders and all Hispanic patients being complete responders. In other studies, AA subtype, current episode and disease duration, and age at first episode were associated with efficacy. Nail involvement and the presence of other autoimmune diseases were not evaluated in these studies.<sup>2,7</sup> Race has never been assessed in prior studies.

Among patients that temporarily discontinued tofacitinib, all had minimal or transient hair loss. Three patients held their therapies for a few weeks, because of COVID-19. None had significant hair loss. Conversely, two patients lost all regrown hair, after treatment ended because of a lack

of insurance. In a prospective trial, about a third of study patients were available at a 3-month follow-up after tofacitinib discontinuation. Hair loss was present in all of them after a median of 2 months.<sup>2</sup>

The safety data in the present cohort was promising. Recent retrospective studies analyzing the safety of tofacitinib for other indications support a positive safety profile of tofacitinib longer-term.<sup>9,10</sup> These retrospective studies, along with the positive safety data, provide us with a better safety outlook in regard to the long-term real-world treatment of AA with tofacitinib.

Limitations of this study include selection bias, variable follow-up times, lack of controls and small sample.

In conclusion, oral tofacitinib may be an effective long-term treatment for AA in carefully selected patients.

## Financial support

None declared.

## Authors' contributions

Xinaida Taligare V. Lima: Approval of the final version of the manuscript; critical literature review; data collection, analysis and interpretation; manuscript critical review; preparation and writing of the manuscript; statistical analysis; study conception and planning.

Melissa Bambery: Approval of the final version of the manuscript; critical literature review; manuscript critical review; preparation and writing of the manuscript; study conception and planning.

Maria Beatrice Alora: Approval of the final version of the manuscript; critical literature review; effective participation in research orientation; intellectual participation in propaedeutic and/or therapeutic management of studied cases; manuscript critical review; preparation and writing of the manuscript; study conception and planning.

## Conflicts of interest

Xinaida Taligare V. Lima serves on the speakers' bureau for Abbvie.

Melissa Bambery has no relevant conflicts of interest.




Maria Beatrice Alora has been an investigator for Abbvie, Janssen, Celgene, Eli Lilly, Pfizer, Inc., Novartis, Concert Pharmaceuticals.

## References

1. Lee HH, Gwillim E, Patel KR, Hua T, Rastogi S, Ibler E, et al. Epidemiology of alopecia areata, ophiasis, totalis, and universalis: A systematic review and meta-analysis. *J Am Acad Dermatol.* 2020;82:675–82.
2. Crispin MK, Ko JM, Craiglow BC, Li S, Shankar G, Urban JR, et al. Safety and efficacy of the JAK inhibitor tofacitinib citrate in patients with alopecia areata. *JCI Insight.* 2016;1:e89776.
3. Ibrahim O, Bayart CB, Hogan S, Piliang M, Bergfeld WF. Treatment of Alopecia Areata With Tofacitinib. *JAMA Dermatol.* 2017;153:600–2.
4. Jabbari A, Nguyen N, Cerise JE, Ulerio G, Jong A, Clynes R, et al. Treatment of an alopecia areata patient with tofacitinib results in regrowth of hair and changes in serum and skin biomarkers. *Exp Dermatol.* 2016;25:642–3.
5. Jabbari A, Sansaricq F, Cerise J, Chen JC, Bitterman A, Ulerio G, et al. An Open-Label Pilot Study to Evaluate the Efficacy of Tofacitinib in Moderate to Severe Patch-Type Alopecia Areata, Totalis, and Universalis. *J Invest Dermatol.* 2018;138:1539–45.
6. Liu LY, Craiglow BG, Dai F, King BA. Tofacitinib for the treatment of severe alopecia areata and variants: A study of 90 patients. *J Am Acad Dermatol.* 2017;76:22–8.
7. Park HS, Kim MW, Lee JS, Yoon HS, Huh CH, Kwon O, et al. Oral tofacitinib monotherapy in Korean patients with refractory

moderate-to-severe alopecia areata: A case series. *J Am Acad Dermatol.* 2017;77:978–80.

8. Phan K, Sebaratnam DF. JAK inhibitors for alopecia areata: a systematic review and meta-analysis. *J Eur Acad Dermatol Venereol.* 2019;33:850–6.
9. Burmester GR, Curtis JR, Yun H, FitzGerald O, Winthrop KL, Azevedo VF, et al. An Integrated Analysis of the Safety of Tofacitinib in Psoriatic Arthritis across Phase III and Long-Term Extension Studies with Comparison to Real-World Observational Data. *Drug Safety.* 2020;43:379–92.
10. Kremer JM, Bingham CO, Cappelli LC, Greenberg JD, Madsen AM, Geier J, et al. Postapproval Comparative Safety Study of Tofacitinib and Biological Disease-Modifying Antirheumatic Drugs: 5-Year Results from a United States-Based Rheumatoid Arthritis Registry. *ACR Open Rheumatol.* 2021;3:173–84.

Xinaida Taligare Vasconcelos Lima <sup>a,b</sup>,  
Melissa Bambery <sup>a</sup>, Maria Beatrice Alora <sup>a,\*</sup>

<sup>a</sup> *Clinical Unit for Research Trials in Skin, Massachusetts General Hospital, Boston, Massachusetts, United States*

<sup>b</sup> *Dermatology Division, Internal Medicine Department, Universidade Federal do Ceará, Fortaleza, CE, Brazil*

Corresponding author.

E-mail: [harvardskinstudies@mgh.harvard.edu](mailto:harvardskinstudies@mgh.harvard.edu) (M.B. Alora).

Received 22 February 2022; accepted 18 May 2022;

Available online 20 January 2023

<https://doi.org/10.1016/j.abd.2022.05.002>

0365-0596/ © 2022 Sociedade Brasileira de Dermatologia.

Published by Elsevier España, S.L.U. This is an open access article under the CC BY license (<http://creativecommons.org/licenses/by/4.0/>).

## Correlation between skin patch testing and clinical outcome in total knee arthroplasty, a serial prospective study<sup>☆</sup>



Dear Editor,

Metal Allergic Contact Dermatitis (ACD) has a wide distribution, in which the main allergens involved are nickel, chromium and cobalt.<sup>1</sup> Contact of these substances with the skin of a previously sensitized individual triggers an inflammatory response that can be diagnosed through patch testing.<sup>2,3</sup>

Conjectures have been made on whether it would be possible to develop an allergy to metals from implants such as plates, screws, and joint replacements,<sup>4,5</sup> and what could be its clinical repercussions. Would previously allergic patients have an increased risk of failure with a traditional implant? In addition, metallic components tend to be the main suspects; however, joint replacements often use cement composed of polymethylmethacrylate. There

is substantial evidence of the allergenic characteristics of acrylates present in dental resin and gel nails.<sup>6,7</sup>

The primary objective of this study was to assess the presence of allergic sensitization through patch testing after Total Knee Arthroplasty (TKA) and to assess a possible correlation between a positive patch test and clinical outcome. Finally, we authors intended to determine whether the test might influence the choice of implant.

Patients with inflammatory, autoimmune, or immunosuppressive diseases; systemic use of corticosteroids or immunosuppressants; use of topical corticosteroids at the application site; evidence of infection by the human immunodeficiency virus; the presence of atopic dermatitis; or

**Table 1** Demographic, clinical and surgery data from the patients submitted to total knee arthroplasty.

Number of patients	14
Minimum age (years)	54
Maximum age (years)	85
Female	9
Male	4
Past history of metal allergy	2
Complications (infection)	2
Loss of follow-up	5

<sup>☆</sup> Study conducted at the Institute of Orthopedics and Traumatology, Hospital das Clínicas, Universidade de São Paulo, SP, Brazil.